Indonesian Journal of Global Health Research
Volume 8 Number 6, December 2026
e-ISSN 2715-1972; p-ISSN 2714-9749
http://jurnal.globalhealthsciencegroup.com/index.php/IJGHR

IGA VASCULITIS FOLLOWING TETANUS-DIPHTHERIA TOXOID BOOSTER VACCINATION IN A 7-YEAR OLD GIRL: A CASE REPORT WITH WHO AEFI CAUSALITY ASSESSMENT

Gede Ananta Wijaya*, Gusti Ayu Sri Ari Swandewi, Romy Windiyanto
Department of Child Health, RSUD Sanjiwani, Jl. Ciung Wanara-Gianyar No. 2, Gianyar, Bali 80511, Indonesia
*odeananta@gmail.com

ABSTRACT

Immunoglobulin A vasculitis (IgAV) is the most common small-vessel vasculitis in children. Although reported after vaccination, causality remains uncertain. Objective to report pediatric IgAV after tetanus-diphtheria (Td) booster vaccination and assess causality using the World Health Organization (WHO) adverse event following immunization (AEFI) tool. We describe the presentation, diagnostic evaluation, management, and clinical course of a 7-year-old girl who developed symptoms after Td booster vaccination during Indonesia's School Immunization Month (BIAS) program. Diagnosis was evaluated using the EULAR/PRINTO/PRES classification criteria, and causality was assessed using the WHO AEFI framework. Approximately 24 hours after vaccination, the patient developed palpable purpura predominantly affecting the lower extremities and gluteal region, accompanied by arthralgia of the elbows, wrists, and knees, and abdominal pain with nausea and vomiting. The platelet count was $382 \times 10^3/\mu L$; renal function was normal, and initial urinalysis showed neither hematuria nor proteinuria. Clinical findings fulfilled the EULAR/PRINTO/PRES classification criteria for IgAV. The patient received corticosteroids and improved clinically. WHO AEFI assessment classified the event as indeterminate. The temporal relationship warrants documentation but does not establish causation. The 24-hour interval, absence of specific immunological evidence, and possibility of an unrecognized infection or spontaneous disease limit causal attribution. Normal initial urinary findings do not exclude subsequent renal involvement. This case highlights systematic AEFI reporting, standardized causality assessment, and continued renal monitoring. A single case cannot establish an increased population-level risk of IgAV following Td vaccination.

Keywords: adverse event following immunization; BIAS; case report henoch-schonlein purpura; IgA vasculitis; tetanus-diphtheria vaccine

How to cite (in APA style)
Wijaya, G. A., Swandewi, G. A. S. A., & Windiyanto, R. (2026). IgA Vasculitis Following Tetanus-Diphtheria Toxoid Booster Vaccination in a 7-Year Old Girl: A Case Report with WHO AEFI Causality Assessment. Indonesian Journal of Global Health Research, 8(6), 1463–1472. https://doi.org/10.37287/ijghr.v8i6.2995.

INTRODUCTION

Immunoglobulin A vasculitis (IgAV), formerly known as Henoch–Schönlein purpura (HSP), is the most common systemic small-vessel vasculitis in children. It is characterized by IgA1-dominant immune complex deposition in small blood vessels, resulting in inflammation that predominantly affects the skin, gastrointestinal tract, joints, and kidneys. The typical clinical manifestations include non-thrombocytopenic palpable purpura, arthralgia or arthritis, abdominal pain, and renal involvement, which may range from asymptomatic hematuria and proteinuria to clinically significant nephritis. Although IgAV predominantly affects children, its epidemiological distribution varies across geographical regions and populations. Recent evidence estimates its annual incidence at approximately 6.8–30 cases per 100,000 children, highlighting its importance as a common pediatric vasculitic disorder (Oni et al., 2024; Hu et al., 2024). The EULAR/PRINTO/PRES classification criteria provide an established framework for classifying childhood IgAV, requiring purpura or petechiae with lower-limb predominance, accompanied by at least one additional feature, including acute abdominal pain, arthritis or arthralgia, renal involvement, or characteristic histopathological findings (Filippatos et al., 2026).

The pathogenesis of IgAV is complex and multifactorial, involving interactions among genetic susceptibility, immune dysregulation, and environmental exposures. Current evidence implicates the production of aberrantly glycosylated IgA1, the formation of IgA1-containing immune complexes, complement activation, and inflammatory responses involving neutrophils and vascular endothelial cells. These mechanisms contribute to small-vessel inflammation and subsequent tissue injury (Hu et al., 2024; Filippatos et al., 2026). Among the recognized environmental triggers, infections, particularly upper respiratory tract infections, are frequently reported before disease onset. Group A streptococcal infections and several viral and other respiratory pathogens have been associated with the development of IgAV. However, the identification of an infectious exposure before symptom onset does not necessarily establish its direct causal role in an individual patient. In addition to infections, certain medications and immunological exposures, including vaccination, have been described in temporal association with IgAV (Bonetto et al., 2016; Filippatos et al., 2026).

Several case reports have documented the occurrence of IgAV or other forms of vasculitis following different vaccinations, including influenza, hepatitis A and B, rabies, bacillus Calmette–Guérin (BCG), COVID-19, and tetanus-containing vaccines. Of particular relevance, Kong et al. (2016) reported a case of Henoch–Schönlein purpura following tetanus toxoid vaccination, suggesting that a similar temporal association has previously been documented. Nevertheless, the occurrence of vasculitis following immunization does not necessarily indicate a vaccine-induced pathological process. A systematic literature review by Bonetto et al. (2016) found that the available evidence was insufficient to establish a causal relationship between vaccination and vasculitis. Most reported cases were based on individual clinical observations, while larger and higher-quality studies did not demonstrate a consistent causal association. More recent evidence also emphasizes the importance of distinguishing epidemiological associations from coincidental events and recognizes that available pediatric vaccine studies have not demonstrated a consistent excess risk of IgAV (Filippatos et al., 2026). Therefore, the potential relationship between vaccination and IgAV remains an important issue in vaccine safety surveillance and requires careful individual assessment rather than assumptions based solely on temporal proximity.

In this context, the present case describes a 7-year-old girl who developed clinical manifestations of IgAV approximately 24 hours after receiving a tetanus-diphtheria (Td) booster vaccination through Indonesia's School-Based Immunization Program (Month of School Immunization [BIAS]). The relatively short interval between vaccination and symptom onset provides an opportunity to examine the clinical presentation, diagnostic considerations, and potential temporal association between Td immunization and IgAV. This report aims to document the clinical course and diagnostic findings, evaluate the suspected adverse event using the World Health Organization (WHO) adverse events following immunization (AEFI) causality assessment framework, and highlight the importance of systematic vaccine safety surveillance and appropriate long-term renal monitoring in children presenting with IgAV after immunization. Importantly, this report does not seek to establish a definitive causal relationship between Td vaccination and IgAV but rather to contribute to the clinical documentation and evidence-based assessment of suspected post-immunization events. The aims of the study To report a case of IgA vasculitis occurring after Td booster vaccination and to assess causality using WHO AEFI tool.

METHOD

Study Design and Reporting Guidelines

This study employed a descriptive single-patient case report design to document the clinical presentation, diagnostic evaluation, management, and outcome of immunoglobulin A vasculitis (IgAV) occurring following tetanus-diphtheria (Td) booster vaccination in a 7-year-old girl. The report focuses on the clinical characteristics, temporal relationship between vaccination and symptom onset, diagnostic confirmation, and assessment of the potential association between immunization and the reported adverse event.

The manuscript was prepared in accordance with the CARE (CAse REport) guidelines to ensure completeness, transparency, and consistency in reporting patient information, clinical findings, diagnostic assessment, therapeutic interventions, clinical timeline, and follow-up outcomes.

Patient Information and Data Collection

Clinical information was obtained from the patient's medical records, clinical history, physical examination, laboratory investigations, and relevant information regarding previous immunization and vaccination history. Additional information regarding the onset and progression of symptoms was obtained from the patient's parent or legal guardian and the treating medical team. The information collected included demographic characteristics, presenting complaints, relevant medical history, history of recent infections, medication exposure, allergy history, previous immunization history, details of the Td booster vaccination, and the chronological development of clinical manifestations. Particular attention was given to the interval between Td vaccination and the initial appearance of symptoms, including palpable purpura, arthralgia, and gastrointestinal manifestations.

Clinical and Diagnostic Assessment

The diagnosis of IgA vasculitis was established based on clinical manifestations and laboratory findings, using the European League Against Rheumatism (EULAR), Pediatric Rheumatology International Trials Organization (PRINTO), and Pediatric Rheumatology European Society (PRES) classification criteria. The diagnostic assessment included the identification of non-thrombocytopenic palpable purpura predominantly involving the lower extremities, accompanied by at least one supporting clinical manifestation, including abdominal pain, acute-onset arthralgia or arthritis, renal involvement, or characteristic histopathological findings. Laboratory investigations included complete blood count, platelet count, renal function assessment, and urinalysis to evaluate possible renal involvement and exclude relevant alternative diagnoses. Histopathological examination was not performed in this patient.

Clinical Management and Follow-up Assessment

Clinical management was documented descriptively, including the pharmacological intervention, corticosteroid administration, dosage adjustments, clinical response, and monitoring during hospitalization. The patient's clinical progress was evaluated based on changes in skin manifestations, joint symptoms, gastrointestinal complaints, vital signs, renal function, and urinalysis findings. Renal monitoring was considered an important component of the clinical assessment because renal manifestations may develop after the initial presentation of IgA vasculitis. Long-term follow-up was recommended to monitor blood pressure, urinalysis, and urinary protein excretion.

WHO AEFI Causality Assessment

The potential association between Td booster vaccination and the onset of IgA vasculitis was evaluated using the World Health Organization (WHO) framework for the causality assessment of adverse events following immunization (AEFI). The assessment considered the validity of the clinical diagnosis, temporal relationship between vaccination and symptom onset, biological plausibility, previously established evidence of vaccine-associated events, potential alternative etiologies, and other available clinical and laboratory information. Particular consideration was given to the possibility of coincidental disease occurrence, including undetected subclinical infection, as well as the limitations of establishing a direct causal relationship from an individual case report. The causality classification was interpreted according to the applicable WHO AEFI assessment algorithm and available case-investigation information. The findings were reported as an individual case assessment and were not interpreted as evidence of a population-level increase in vaccine-related risk.

Ethical Considerations

Written informed consent for publication of the clinical information and accompanying clinical photographs was obtained from the patient's parent or legal guardian. Patient confidentiality and anonymity were maintained throughout the preparation of this manuscript.

The reported event was submitted to the local health authority's AEFI surveillance system. [Insert the institutional ethical approval or exemption statement, including the committee name and approval/reference number, if applicable.]

Data Analysis

The data were analyzed descriptively and presented in narrative form, supported by clinical photographs, laboratory findings, and a chronological clinical timeline. No statistical analysis was performed because this report involved a single patient.

RESULT

A 7-year-old girl presented with a red rash that had been present for 3 days on both upper and lower extremities, along with progressively worsening joint pain in both elbows, hands, and knees. She also complained of abdominal pain accompanied by nausea and vomiting that had begun 3 days earlier. She denied any previous medical history and any recent infections or medication use. She also denied any food or medication allergies. She had recently received a booster dose of intramuscular tetanus toxoid vaccine approximately 1 day before the onset of these symptoms. She also denied any history of similar symptoms with previous immunizations. She had consulted a midwife and was given anti-allergy medication, but her symptoms worsened.



Figure 1. Palpable purpura on lower extremities extending to gluteal area (original photo)

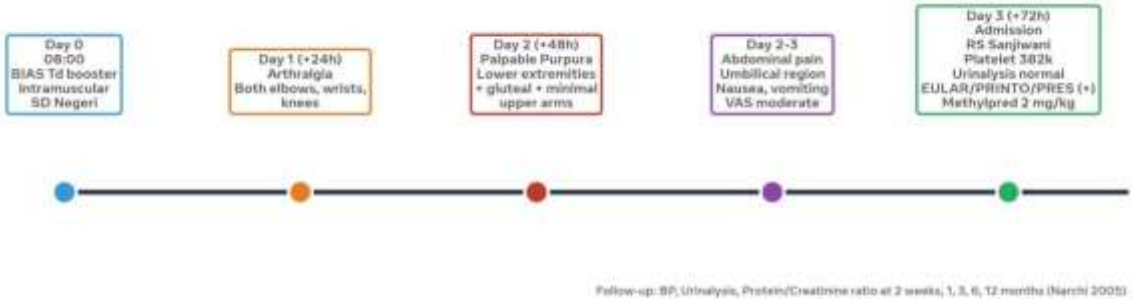

Figure 2. Clinical timeline of IgA vasculitis symptoms following Td booster vaccination. BIAS = School Children Immunization Month. Follow-up recommendation per Narchi 2005.

On examination, the patient was fully conscious and well hydrated. Vital signs were normal for his age. On physical examination, the skin revealed multiple, well-defined, miliary-plaque-shaped, confluent erythematous macules distributed bilaterally, mainly on the extensor surfaces of both lower extremities, starting from the feet and extending to the bilateral inguinal and gluteal areas. There was also a minimal purpuric rash on both upper arms. Tenderness was also found in both elbows and knees. Cardiovascular examination was within normal limits, with normal heart sounds and no additional murmurs. Lung examination was normal with no additional sounds. Abdominal examination revealed tenderness in the umbilical region and no organomegaly. Neurological examination was also within normal limits.

Laboratory examination showed normal platelets 382 x 10^3/µL, normal kidney function, and normal urinalysis without proteinuria or hematuria. The diagnosis of HSP or IgA Vasculitis was established based on EULAR/PRINTO/PRES criteria and the patient was started on intravenous Corticosteroids (Methylprednisolone) at a dose of 2 mg/kgBW/day and the patient responded adequately to therapy so the dose was gradually reduced after 72 hours of treatment to 1.5 mg/kgBW/day orally for 48 hours then 1 mg/kgBW/day orally for 48 hours. The patient underwent blood pressure monitoring and urinalysis throughout the course of treatment. No proteinuria or hematuria was observed during initial treatment. The patient's parents provided informed consent for publication and documentation of clinical photographs. The case has been reported to the local Health Office's AEFI surveillance system.

Table 1.
EULAR/PRINTO/PRES IgA Vasculitis Classification Criteria (Ozen et al 2010)

Criteria	Description
Mandatory Criteria	*Palpable purpura,* usually on the lower extremities, not associated with thrombocytopenia
Plus at least 1 of the supporting criteria	1. Diffuse colicky abdominal pain with acute onset, assessed by history and physical examination. May include intussusception and gastrointestinal bleeding. 2. Histopathology: Typical leukocytoclastic vasculitis *(* LCV) with predominance of IgA deposits or proliferative glomerulonephritis with predominance of IgA deposits 3. Acute-onset arthritis is defined as joint swelling or pain with limited motion. Acute-onset arthralgia is defined as joint pain without joint swelling or limited motion. 4. Renal involvement (Proteinuria: > 0.3g/24 hours or urine albumin to creatinine ratio > 30 mg/mmol in a random morning urine sample; and/or hematuria, red blood cell casts: >5 red blood cells per high-power field or ≥ 2+ on dipstick or red blood cell casts in urine sediment)

In this patient: Mandatory criteria (+), Abdominal pain (+), Arthralgia (+), Renal involvement (-), Histopathology not performed. Clinical diagnosis met.

Table 2.
Laboratory Examination Results

Parameter	Results	Normal Values	Unit
Complete Blood Count			
Hemoglobin	11.1	11.0 – 16.0	g/dL
Leukocytes	9.56	4.00 – 10.00	10^3/µ L
Platelets	382	150 – 450	10^3/µ L
Erythrocytes	3.87	3.50 – 5.50	10^6/µ L
Random Glucose	86	80 - 120	mg/dL
Alkaline Phosphatase	186	53 – 128	U/L
SGOT	25	< 35	U/L
SGPT	8	< 41	U/L
Creatinine	0.34	0.2 – 0.7	mg/dL
urea	27.4	18 - 55	mg/dL
Urinalysis			
Color	Yellow	Yellow	
Specific gravity	1,010	1,003 – 1,030	
pH	6.0	6.0 – 6.5	
Albumin	-		
Glucose	-	-	
Bilirubin	-	-	
Urobilinogen	-	-	
Ketone	-	-	
Nitrite	-	-	
Erythrocytes	0-1	< 2	/LPB
Leukocytes	1-2	0 - 5	/LPB
Epithelial Cells	0-1	0-2	/LPK
Calcium Oxalate	-	-	
Gout	-	-	
Bacteria	-	-	
Mold	-	-	

Table 3.
WHO AEFI Causality Assessment (Tozzi et al 2013) Adapted to This Case

WHO AEFI Item	Assessment in this case	Result
1. Diagnosis validity (EULAR/PRINTO/PRES)	Palpable purpura lower extremity + arthralgia + abdominal Platelet normal, no thrombocytopenia	Diagnosis valid
2. Temporal eligibility (Time window)	Onset 24h after Td booster Previous Td-containing reports: 1 day - 12 weeks	Eligible but short interval raises plausibility questio
3. Known evidence (Bonetto et al 2016, Kong et al 2	Rare case reports post Td Systematic review: insufficient evidence for causality	Weak signal
4. Alternative causes (infection, drugs)	No recent infection, no new drugs Subclinical infection cannot be fully excluded No microbiology workup	Possible alternative not excluded
5. Biological plausibility	IgA1 immune complex needs >24h for primary response Memory response hypothesis possible but no IgA level / bio	Plausibility indeterminate
FINAL CLASSIFICATION	Temporal association, insufficient evidence for definitive ca	INDETERMINATE (Coincidental / Unclassifiable)

Final classification: INDETERMINATE (Coincidental / Unclassifiable) - Temporal association, insufficient evidence for a definitive causal relationship

DISCUSSION

Immunoglobulin A vasculitis (IgAV), formerly known as Henoch–Schönlein purpura, is the most common systemic small-vessel vasculitis in children. Its pathogenesis is considered multifactorial, involving genetic susceptibility, dysregulated immune responses, and environmental triggers. Although the precise mechanisms remain incompletely understood, current evidence implicates the production of aberrantly glycosylated IgA1, the formation of IgA1-containing immune complexes, complement activation, and subsequent inflammatory injury to small blood vessels. Infections, particularly upper respiratory tract infections, are among the most frequently reported antecedent events in pediatric IgAV. Nevertheless, vaccination has also been described in individual reports as a potential temporal antecedent to disease onset. The distinction between temporal association and causal attribution remains essential, as the available evidence concerning vaccine-associated vasculitis is predominantly derived from case reports and observational studies, which are inherently limited in establishing causality (Bonetto et al., 2016; Hu et al., 2024; Filippatos et al., 2026).

In the present case, a 7-year-old girl developed palpable purpura predominantly involving the lower extremities, arthralgia affecting multiple joints, and gastrointestinal manifestations characterized by abdominal pain, nausea, and vomiting approximately 24 hours after receiving a TD booster vaccination through the School-Based Immunization Program (Month of School Immunization [BIAS]). Laboratory investigations demonstrated a normal platelet count of $382 \times 10^3/\mu L$, preserved renal function, and an initially normal urinalysis without proteinuria or hematuria. The combination of lower-limb-predominant palpable purpura without thrombocytopenia and accompanying articular and gastrointestinal manifestations fulfills the EULAR/PRINTO/PRES classification criteria for childhood IgAV (Ozen et al., 2010). These findings support the clinical diagnosis of IgAV; however, establishing the diagnosis and determining its potential precipitating factor represents two distinct clinical and scientific assessments. The presence of a characteristic clinical phenotype does not, by itself, establish an etiological relationship with a preceding immunization.

A central consideration in this case is the distinction between the temporal sequence of vaccination and disease onset and a demonstrable causal relationship. Although temporality is a necessary component of causal inference, the occurrence of a clinical event after immunization does not necessarily indicate that vaccination caused the event. IgAV may arise spontaneously or following exposure to several environmental and infectious triggers. Accordingly, the observed sequence may represent a vaccine-associated immune response, a possible contribution of vaccination in a susceptible individual, or a coincidental occurrence unrelated to immunization. This distinction is

particularly important in children, in whom IgAV may develop following clinically unrecognized infections or without an identifiable preceding trigger. Therefore, the approximately 24-hour interval observed in this patient should be interpreted cautiously and within the broader context of the disease's natural history and established evidence concerning vaccine safety (Bonetto et al., 2016; Filippatos et al., 2026).

The relatively short interval between vaccination and symptom onset also raises important questions regarding biological plausibility. Current understanding of IgAV pathophysiology emphasizes the contribution of aberrantly glycosylated IgA1, immune-complex formation, complement activation, and inflammatory interactions involving neutrophils and vascular endothelial cells. These processes are believed to contribute to small-vessel inflammation and the characteristic clinical manifestations of the disease (Hu et al., 2024). Although immunization can stimulate innate and adaptive immune responses, the development of a newly established antigen-specific adaptive immune response and subsequent pathogenic immune-complex formation would generally require a longer period than 24 hours. Nevertheless, the possibility that vaccination may have modulated a pre-existing immune response, including an immunological memory response in a susceptible individual, cannot be entirely excluded. Such a mechanism remains hypothetical in the present case because no specific immunological investigations, including measurements of galactose-deficient IgA1, circulating immune complexes, complement activation, or relevant immune-response markers, were performed. Consequently, a direct immunopathological mechanism linking Td vaccination to the development of IgAV cannot be established from the available clinical evidence.

The possibility of alternative triggering factors further complicates causal interpretation. In this case, the patient's history did not indicate a recent clinically apparent infection or exposure to newly prescribed medications before symptom onset. Although this information reduces the likelihood of certain recognized triggers, it does not definitively exclude alternative etiologies. Subclinical or recently resolved respiratory and gastrointestinal infections may occur without prominent symptoms, while infection-associated immune activation may persist beyond the clinically apparent infectious period. Recent literature continues to highlight the importance of infectious exposures in pediatric IgAV, particularly respiratory pathogens, while emphasizing that temporal proximity alone cannot establish the causative role of a specific pathogen in an individual patient (Filippatos et al., 2026). Moreover, no comprehensive microbiological or immunological investigation was available in the present case to exclude occult infection or identify an alternative immunological trigger. Therefore, the possibility of infection-associated or spontaneously occurring IgAV remains relevant when interpreting the temporal association with Td vaccination.

Previous reports have documented the occurrence of IgAV and other forms of vasculitis following several types of vaccination, including influenza, hepatitis, rabies, BCG, tetanus-containing, and COVID-19 vaccines. Of particular relevance, Kong et al. (2016) described a case of Henoch–Schönlein purpura following tetanus toxoid vaccination, providing a previously reported example of a similar temporal association. Nevertheless, individual case reports cannot establish an increased incidence of disease following vaccination or distinguish vaccine-related events from coincidental occurrences. A systematic review by Bonetto et al. (2016), which evaluated published evidence concerning vasculitis as an adverse event following immunization, identified substantial limitations in the available literature, particularly the predominance of spontaneous reports and case-based evidence. These limitations prevent definitive conclusions regarding a causal relationship between vaccination and the development of vasculitis. Accordingly, the present case adds to the clinical documentation of IgAV occurring after a Td-containing vaccine but should not be interpreted as evidence that Td vaccination increases the risk of IgAV in children.

To systematically evaluate the potential relationship between vaccination and the reported clinical event, the World Health Organization (WHO) framework for the causality assessment of adverse

events following immunization (AEFI) provides an appropriate standardized approach. The WHO methodology incorporates assessment of diagnostic validity, temporal compatibility, established evidence of causal association, alternative etiologies, and other relevant factors that may support or contradict a causal relationship. The revised WHO classification also distinguishes events with a consistent causal association, events with an inconsistent causal association (coincidental), indeterminate events, and unclassifiable events (World Health Organization [WHO], 2021). In the present case, the clinical diagnosis of IgAV was supported by characteristic manifestations and the absence of thrombocytopenia, while the temporal relationship with Td booster vaccination was clearly documented. However, the available information did not establish a specific causal mechanism or provide sufficient evidence to attribute the disease directly to the vaccine. Consequently, the reported classification of indeterminate may be appropriate if the completed WHO assessment demonstrates a compatible temporal relationship but insufficient definitive evidence to establish causation. Importantly, the indeterminate category should not be used interchangeably with the coincidental or unclassifiable categories, as each represents a distinct outcome within the WHO algorithm. Thus, the findings should be interpreted as a temporal association with unresolved causality rather than as confirmed vaccine-induced vasculitis.

The clinical response to treatment should also be interpreted independently of the assessment of vaccine causality. The patient received intravenous methylprednisolone at an initial dose of 2 mg/kg/day, followed by a gradual reduction in dosage after clinical improvement. The observed response is consistent with the treatment-responsive inflammatory manifestations of IgAV; however, improvement following corticosteroid administration does not identify the initiating trigger or establish a causal relationship with prior vaccination. Furthermore, the clinical course of childhood IgAV is frequently self-limiting, and spontaneous improvement may occur during the natural progression of the disease. Current evidence-based recommendations recommend that treatment decisions should be guided by the severity and organ involvement of IgAV, particularly gastrointestinal and renal manifestations, rather than by the presumed identity of an unconfirmed trigger (Castañeda et al., 2024; Oni et al., 2025).

Renal involvement remains one of the most clinically important considerations in the long-term management of children with IgAV. Although the present patient demonstrated normal initial renal function and urinalysis without detectable proteinuria or hematuria, the absence of renal abnormalities at presentation does not exclude the subsequent development of IgAV-associated nephritis. Renal manifestations may emerge after the initial extrarenal symptoms and can have important implications for long-term prognosis. Recent recommendations from the International Pediatric Nephrology Association (IPNA) emphasize that follow-up assessments should specifically aim to detect delayed renal involvement, even in children with initially normal urinalysis findings. These recommendations support regular monitoring of blood pressure, urinalysis, and urinary protein excretion, with at least monthly assessment during the first six months after diagnosis in children with IgAV (Vivarelli et al., 2025). Therefore, continued renal surveillance is particularly important in this patient, and the initial normal laboratory findings should not be considered as sufficient evidence to discontinue follow-up. Longitudinal documentation of renal parameters and clinical outcomes would provide a more comprehensive understanding of the disease course.

Several limitations should be acknowledged when interpreting the findings of this case report. First, no specific immunological investigations were performed to demonstrate a mechanistic relationship between Td vaccine antigens and the immunopathological processes underlying IgAV. Second, subclinical or recently resolved infections could not be definitively excluded because comprehensive microbiological investigations were unavailable. Third, information concerning the patient's previous immune responses to vaccination, the complete immunization history, and detailed vaccine product characteristics were limited. Fourth, the relatively short interval between vaccination and symptom onset raises questions regarding biological plausibility, and the absence of longitudinal immunological observations limits further interpretation. Fifth, as this report describes

a single patient without a comparison group or population-based denominator, it cannot estimate the incidence of IgAV following Td vaccination or determine whether the observed event occurred more frequently than expected in the general pediatric population.

Despite these limitations, this case contributes to the clinical literature by documenting IgAV occurring approximately 24 hours after Td booster vaccination in a school-aged child, with a characteristic combination of cutaneous, musculoskeletal, and gastrointestinal manifestations. It also illustrates the importance of distinguishing clinical diagnosis from causal attribution when evaluating suspected vaccine-related adverse events. Detailed immunization history, systematic evaluation of alternative etiologies, standardized WHO AEFI causality assessment, and appropriate longitudinal renal monitoring are essential components of the clinical evaluation and reporting of suspected adverse events following immunization. Further well-designed epidemiological studies and standardized pharmacovigilance investigations are required to clarify whether any specific vaccine-related risk exists. Until stronger evidence becomes available, the present observation should be interpreted as an individual clinical event with a temporal association with Td vaccination, without implying a definitive causal relationship or a change in the established benefit–risk profile of Td immunization. The established public health benefits of vaccination in preventing tetanus and diphtheria should therefore remain central to clinical and public health decision-making.

CONCLUSION

This case report describes IgA vasculitis (IgAV) in a 7-year-old girl who developed clinical manifestations approximately 24 hours after receiving a tetanus-diphtheria (Td) booster vaccination through Indonesia's School Immunization Month (BIAS) program. The diagnosis was based on the EULAR/PRINTO/PRES classification criteria, with palpable purpura predominantly affecting the lower extremities, accompanied by arthralgia and abdominal pain. The platelet count was within the normal range, and the initial urinalysis showed no evidence of hematuria or proteinuria. Based on the WHO adverse event following immunization (AEFI) causality assessment framework, the case was classified as indeterminate, indicating a temporal association between vaccination and symptom onset without sufficient evidence to establish a definitive causal relationship. The possibility of an underlying subclinical infection or spontaneous disease occurrence could not be excluded, and no specific immunological evidence linking the vaccine to the development of IgAV was available. The clinical response to corticosteroid therapy was consistent with an inflammatory condition responsive to immunosuppression; however, this response does not establish the underlying trigger. As a single case report, these findings cannot establish that Td booster vaccination increases the population-level risk of IgAV. The temporal relationship observed in this patient should therefore be interpreted cautiously and should not be regarded as evidence of vaccine-induced disease. The substantial benefits of the BIAS immunization program in preventing potentially life-threatening tetanus and diphtheria remain important. Systematic AEFI reporting, standardized causality assessment, and further documentation of similar cases with adequate clinical follow-up are essential to strengthen vaccine safety surveillance and improve understanding of rare events occurring after immunization.

REFERENCES

Bonetto, C., Trotta, F., Felicetti, P., Alarcón, GS, Santuccio, C., Bachtiar, NS, Pernus, YB, Chandler, R., Girolomoni, G., Hadden, RDM, Kucuku, M., Ozen, S., Pahud, B., Top, K., Varricchio, F., Wise, RP, Zanoni, G., Živković, S., & Bonhoeffer, J. (2016). Vasculitis as an adverse event following immunization: A systematic literature review. *Vaccine, 34* (51), 6641–6651. https://doi.org/10.1016/j.vaccine.2015.09.026

Casini F, et al. Henoch–Schönlein purpura following COVID-19 vaccine in a child: a case report. Ital J Pediatr. 2022;48:158. https://doi.org/10.1186/s13052-022-01351-1

Castañeda, S., Quiroga-Colina, P., Floranes, P., Uriarte-Ecenarro, M., Valero-Martínez, C., Vicente-Rabaneda, E.F., & González-Gay, M.A. (2024). IgA vasculitis (Henoch–Schönlein purpura):

An update on treatment. *Journal of Clinical Medicine, 13* (21), Article 6621. https://doi.org/10.3390/jcm13216621

Felix A, et al. Common seasonal pathogens and epidemiology of Henoch-Schönlein purpura among children. JAMA Netw Open. 2024;7:e245362.

Filippatos, F., Venieri, D., Tsigkrou, E., Karava, V., Miliaraki, M., & Kakleas, K. (2026). Infectious triggers in IgA vasculitis in children: Current evidence, causal attribution and immunopathogenic mechanisms. *Rheumatology International, 46* , Article 267. https://doi.org/10.1007/s00296-026-06295-x

Hu, Y.-C., Yang, Y.-H., & Chiang, B.-L. (2024). Immunoglobulin A vasculitis: The clinical features and pathophysiology. *Kaohsiung Journal of Medical Sciences, 40* (7), 612–620. https://doi.org/10.1002/kjm2.12852

Jennette JC, et al. 2012 revised International Chapel Hill Consensus Conference Nomenclature of Vasculitides. Rheumatoid arthritis. 2013;65:1-11. https://doi.org/10.1002/art.37715

L eung AKC, et al. Henoch-Schönlein Purpura in Children: an updated review. Curr Pediatr Rev. 2020;16:265–76.

Kong, W.-Y., Wan Abdullah, WZA, Gafor, H., Mohd, R., & Cader, R.A. (2016). Henoch–Schönlein purpura after tetanus toxoid vaccination: A case report. *Journal of Clinical Nephrology and Renal Care, 2* , Article 018. https://doi.org/10.23937/2572-3286.1510018

Narchi H. Risk of long-term renal impairment and duration of follow-up recommended for Henoch-Schönlein purpura with normal or minimal urinary findings: a systematic review. Arch Dis Child. 2005;90:916–20. https://doi.org/10.1136/adc.2005.072512

Oni, L., Platt, C., Marlais, M., McCann, L., Barakat, F., Hesseling, M., Cottis, H., Protheroe, S., Haigh, G., Nott, K., Marro, J., King, E., Kelly, J., Sussens, J., Mulvaney, S., Whitby, T., Morgan, I., Sharma, A., Al-Jayyousi, R., ... Dudley, J. (2025). National recommendations for the management of children and young people with IgA vasculitis: A best available evidence, group agreement-based approach. *Archives of Disease in Childhood, 110* (1), 67–76. https://doi.org/10.1136/archdischild-2024-327364

Ozen, S., Pistorio, A., Iusan, SM, Bakkaloglu, A., Herlin, T., Brik, R., Buoncompagni, A., Lazar, C., Bilge, I., Uziel, Y., Rigante, D., Cantarini, L., Hilario, MOE, Silva, CA, Alegria, X., Norambuena, X., Belot, A., Berkun, Y., Ibanez, D., ... Ruperto, N. (2010). EULAR/PRINTO/PRES criteria for Henoch–Schönlein purpura, childhood polyarteritis nodosa, childhood Wegener granulomatosis and childhood Takayasu arteritis: Ankara 2008. Part II: Final classification criteria. *Annals of the Rheumatic Diseases, 69* (5), 798–806. https://doi.org/10.1136/ard.2009.116657

Tozzi AE, et al. Assessment of causality of individual adverse events following immunization (AEFI): A WHO tool for global use. Vaccines. 2013;31:5041–6. https://doi.org/10.1016/j.vaccine.2013.06.065

Trnka P. Henoch–Schönlein purpura in children. J Paediatr Child Health. 2013;49:995–1003

Vivarelli, M., Samuel, S., Coppo, R., Barratt, J., Bonilla-Felix, M., Haffner, D., Gibson, K., Haas, M., Abdel-Hafez, M.A., Adragna, M., Brogan, P., Kim, S., Liu, I., Liu, Z.-H., Mantan, M., Shima, Y., Shimizu, M., Shen, Q., Trimarchi, H., ... Nakanishi, K. (2025). IPNA clinical practice recommendations for the diagnosis and management of children with IgA nephropathy and IgA vasculitis nephritis. *Pediatric Nephrology, 40* (2), 533–569. https://doi.org/10.1007/s00467-024-06502-6

Wang B, et al. The influence of respiratory infections on Henoch-Schönlein purpura in children. BMC Infect Dis. 2025;25:118.

World Health Organization. (2021). *Causality assessment of an adverse event following immunization (AEFI): User manual for the revised WHO classification* (2nd ed., 2019 update). https://www.who.int/publications/i/item/9789241516990