Indonesian Journal of Global Health Research
Volume 8 Number 6, December 2026
e-ISSN 2715-1972; p-ISSN 2714-9749
http://jurnal.globalhealthsciencegroup.com/index.php/IJGHR

SUBCUTANEOUS BOTULINUM TOXIN A FOR POSTHERPETIC NEURALGIA: A CASE REPORT

Dinda Novita Maghfiroh*, Ni Nyoman Ayu Sutrini
Rejuvie Clinic Bali, Jl. Dewi Sri VIII No.B 3-4, Legian, Kuta, Badung, Bali 80361, Indonesia
*dindanovitam77@gmail.com

ABSTRACT
Postherpetic neuralgia (PHN) is persistent neuropathic pain occurring at least 3 months after herpes zoster. Conventional pharmacological and interventional treatments may provide inadequate relief in some patients. Botulinum toxin A has emerged as a potential local treatment for neuropathic pain. To describe the clinical response of postherpetic neuralgia to adjunctive subcutaneous botulinum toxin A injection. A 60-year-old man presented with persistent left-sided thoracic pain for 3 months after herpes zoster. The pain was described as needle-prick-like, associated with numbness and tactile allodynia, and localized to the left anterolateral thoracic region at T6–T7. His visual analogue scale (VAS) score decreased from 9 to 5 after five diode laser sessions but remained symptomatic. One week after the last laser session, 100 units of botulinum toxin A were administered subcutaneously at 2 units per injection point with 2-cm spacing. Pain was reassessed at 3 days, 1 week, and 1 month after injection while diode laser therapy continued. In this case, adjunctive subcutaneous botulinum toxin A was associated with a reduction in VAS from 5 to 3 by day 3, with the score remaining 3 at 1 month.

Keywords: botulinum toxin A; diode laser; neuropathic pain; postherpetic neuralgia; visual analogue scale

How to cite (in APA style)
Maghfiroh, D. N., & Sutrini, N. N. A. (2026). Subcutaneous Botulinum Toxin A for Postherpetic Neuralgia: A Case Report. *Indonesian Journal of Global Health Research*, *8*(6), 779–784. https://doi.org/10.37287/ijghr.v8i6.2738.

INTRODUCTION

Postherpetic neuralgia (PHN) is persistent neuropathic pain that continues for at least 3 months after the onset of herpes zoster. It may present with burning, stabbing, dysesthesia, hyperalgesia, and allodynia. The risk of PHN increases with age, and reported rates among patients with herpes zoster vary substantially across populations (Rohmayanti & Kurniawan, 2023; Yang et al., 2019; Nadiva et al., 2024). The pathogenesis of PHN involves both peripheral and central nervous system changes. Reactivation of varicella-zoster virus can injure sensory dorsal root ganglia and peripheral sensory fibers, producing ectopic activity and peripheral hypersensitivity. Persistent nociceptive input may also contribute to dorsal horn sensitization, altered central pain modulation, neuronal plasticity, and loss of inhibitory control (Liu et al., 2024). These mechanisms can result in chronic pain that substantially affects physical activity, sleep, and psychological well-being (Song et al., 2024).

Management aims to reduce pain and improve quality of life. Common pharmacological options include tricyclic antidepressants, anticonvulsants, topical lidocaine, topical capsaicin, and opioids, while interventional approaches may include peripheral nerve blocks, epidural or sympathetic blocks, radiofrequency procedures, transcutaneous electrical nerve stimulation, and spinal cord stimulation (Song et al., 2024; Gónima Valero et al., 2023; van Wijck et al., 2011; Jeon, 2015). Nevertheless, some patients continue to experience residual pain despite treatment, and prolonged pharmacological therapy may be limited by adverse effects and tolerability (Song et al., 2024; Nalamachu & Morley-Forster, 2012).

Botulinum toxin A (BoNT-A) has attracted interest as a local treatment for PHN. Clinical studies and systematic reviews have reported reductions in pain scores following subcutaneous or intradermal injection over the affected area, although the magnitude and duration of response vary

(Wang & Lin, 2024; Li et al., 2020; Apalla et al., 2013; Chen et al., 2022). A randomized clinical trial involving 100 patients reported comparable efficacy between BoNT-A and pulsed radiofrequency, including improvements in pain and selected patient-reported outcomes through 24 weeks (Chen et al., 2022). A meta-analysis also reported greater pain reduction with BoNT-A than with some conventional analgesic approaches, without a significant increase in adverse effects (Shackleton et al., 2016). Despite these findings, important uncertainties remain regarding patient selection, dose, injection spacing, frequency of repeat treatment, and the influence of age and PHN duration.[15–17] This case report describes the short-term change in pain intensity after adjunctive subcutaneous BoNT-A in a patient with thoracic PHN whose pain persisted despite diode laser therapy.

METHOD

A 60-year-old man with persistent neuropathic pain following herpes zoster was evaluated at a dermatology clinic. The patient had left-sided thoracic pain radiating to the back for approximately 3 months after herpes zoster, accompanied by numbness and tactile allodynia. Clinical examination revealed hyperpigmented macules distributed linearly over the left anterolateral thoracic region corresponding to the T6–T7 dermatomes. Based on the clinical history and examination, the patient was diagnosed with postherpetic neuralgia (PHN).

The patient had previously received acyclovir, mefenamic acid, and vitamin B complex during the acute herpes zoster episode. Due to persistent pain, diode laser therapy was subsequently administered. After five laser sessions, the pain intensity decreased from a VAS score of 9 to 5 but remained clinically significant. As adjunctive treatment, 100 units of botulinum toxin A (BoNT-A) were administered subcutaneously over the affected T6–T7 region, with 2 units per injection point and 2-cm spacing between injection points. The injection was performed 1 week after the last diode laser session. Topical anesthesia was used. Pain intensity was assessed using the visual analogue scale (VAS) before BoNT-A administration and at 3 days, 1 week, and 1 month after injection. Diode laser therapy was continued during the follow-up period. VAS scores were analyzed descriptively by comparing baseline pain intensity with scores at 3 days, 1 week, and 1 month after BoNT-A injection. Changes in VAS scores were expressed as absolute and percentage reductions from baseline. These changes were interpreted alongside the patient's clinical symptoms and findings during follow-up. As this was a single-case report, no inferential statistical analysis was performed.

RESULT

The patient reported a history of chickenpox during elementary school. He had no reported history of heart disease, diabetes, hypercholesterolemia, or kidney disease. He also denied previous pain at the same site. No family member was reported to have chickenpox or herpes zoster. During the acute herpes zoster episode, the patient received acyclovir 800 mg five times daily, mefenamic acid 500 mg three times daily, and vitamin B complex once daily for 1 week. Because the pain did not improve adequately, analgesic treatment was discontinued and diode laser therapy was initiated. The source report describes the initial frequency as every 2 weeks. After five diode laser sessions, the VAS score decreased from 9 to 5, but clinically relevant pain persisted. The baseline and subsequent pain scores are summarized in Table 1.

Dermatological examination showed multiple hyperpigmented macules, round to oval and partly irregular, with well-defined borders and variable size (approximately 2 mm–1 cm), arranged linearly over the left anterior-to-lateral thoracic region corresponding to dermatomes T6–T7. Based on the history and examination, the patient was diagnosed with PHN involving the left T6–T7 thoracic dermatomes.

As adjunctive treatment, 100 units of BoNT-A were administered subcutaneously, with 2 units per injection point and 2-cm spacing over the affected thoracic region (Figure 1). The injection was performed 1 week after the last diode laser session. The source report also states that topical anesthesia was used. After injection, the patient was assessed at 3 days, 1 week, and 1 month and continued to receive diode laser therapy twice weekly.

The VAS score decreased from 5 immediately before BoNT-A injection to 3 at day 3 after injection and remained 3 at 1 month (Table 1). The source report does not describe adverse effects following the injection during the stated observation period.

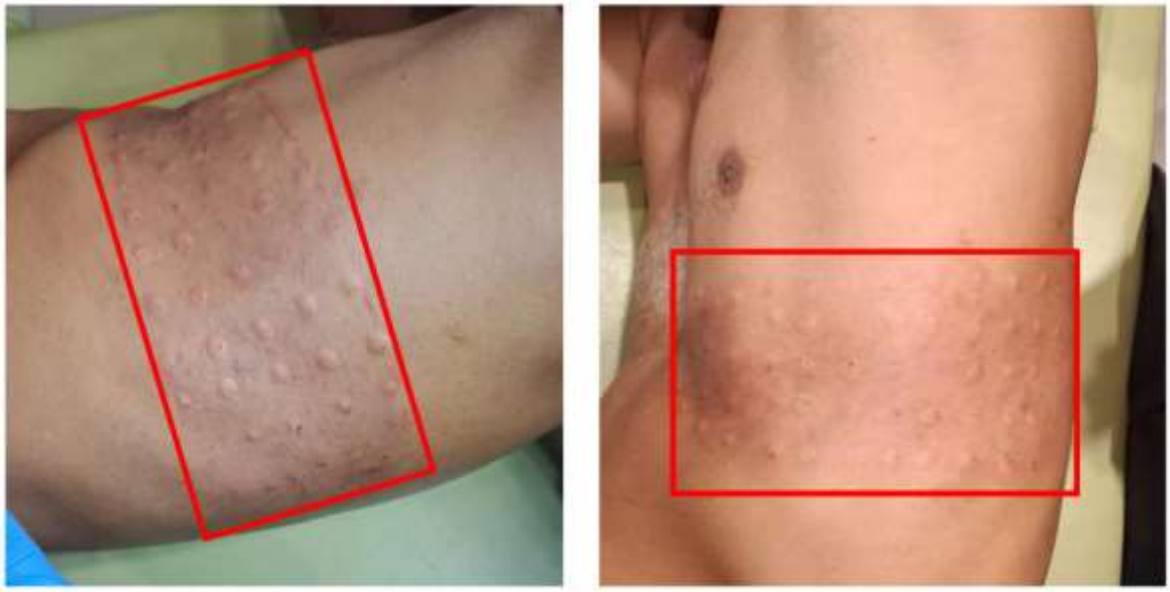

Figure 1. Clinical photographs showing the thoracic area treated with subcutaneous botulinum toxin A (100 units; 2 units per injection point; 2-cm spacing) over the left anterolateral T6–T7 region.

Clinical timeline

The patient initially received acute treatment for herpes zoster with acyclovir, mefenamic acid, and vitamin B complex for one week. Persistent neuropathic pain subsequently led to five sessions of diode laser therapy, resulting in a reduction in VAS score from 9 to 5. One week after the last laser session, subcutaneous BoNT-A was administered at a total dose of 100 U (2 U per injection site, with 2-cm spacing). The VAS score decreased to 3 on day 3 after BoNTD-A administration and remained at 3 at one-month follow-up. Diode laser therapy was continued during the follow-up period.

Table 1.
Change in pain intensity measured by the visual analogue scale after adjunctive botulinum toxin A

Assessment time	VAS score
At PHN diagnosis	9
After five diode laser sessions	5
3 days after botulinum toxin A injection	3
1 month after botulinum toxin A injection	3

Note: VAS = visual analogue scale. The source report states that diode laser therapy continued during follow-up; therefore, the observed change cannot be attributed to botulinum toxin A alone.

DISCUSSION

This case describes a patient with thoracic PHN whose pain improved from VAS 5 to VAS 3 within 3 days after adjunctive subcutaneous BoNT-A and remained at VAS 3 at 1 month. The patient had already achieved partial improvement after five diode laser sessions, from VAS 9 to VAS 5, but

residual pain persisted. Thus, BoNT-A was introduced as an additional local treatment rather than as the sole intervention. The clinical response is consistent with previous literature suggesting that BoNT-A may reduce neuropathic pain in PHN, although responses are not uniform. Systematic reviews and meta-analyses have reported clinically meaningful reductions in pain after local BoNT-A administration, while individual studies have shown variable magnitude and duration of benefit (Wang & Lin, 2024; Shackleton et al., 2016; Ding et al., 2017; Peng & Xia, 2023). A previous case report also described substantial improvement in long-standing PHN and pruritus following BoNT-A (Song et al., 2024). A potential explanation for analgesic activity is the local inhibition of pain-related mediator release from sensory nerve terminals, with additional effects on neuronal signaling involved in pain processing (Apalla et al., 2013; Oliveira et al., 2024). The peripheral component is particularly relevant to local injection over the affected dermatome. However, the precise mechanism of BoNT-A analgesia remains incompletely established, and clinical efficacy may depend on the characteristics of the neuropathic lesion.

The early onset of improvement in this case is notable. The patient's VAS decreased by 2 points within 3 days, whereas some published observations have described an onset of improvement approximately 1 week after injection and persistence of benefit for several weeks to months (Apalla et al., 2013; Liu et al., 2006). Differences in onset may reflect variation in disease duration, age, injection technique, concomitant treatment, and individual response. Injection dose and spacing may also influence treatment response. In the present case, 100 units were distributed at 2 units per point with 2-cm spacing. A 2024 meta-analysis reported that many randomized trials used total doses of 50–100 units with subcutaneous or intradermal injection at approximately 1–2-cm intervals and found mean VAS reductions of about 1.6–1.9 points during 2–8 weeks of follow-up (Wang & Lin, 2024). Other reports have used different doses per point and injection intervals, and there is currently no universally accepted standard for BoNT-A dose or injection technique in PHN (Ri et al., 2021).

Age and duration of PHN may be clinically relevant when interpreting treatment response. Longer-standing neuropathic pain may be associated with persistent structural and functional changes in sensory pathways, potentially reducing responsiveness to local treatment (Ding et al., 2017; Cruces Muñoz, 2024). The patient in this report had a relatively short PHN duration of approximately 3 months, which may have favored a response, although this cannot be established from a single case. The patient's prior treatment is an important confounder. He received acyclovir during the acute herpes zoster episode, and antiviral therapy may reduce viral replication and acute inflammation and may influence the subsequent course of pain (Lim et al., 2024; Johnson, 2002). In addition, diode laser therapy continued during follow-up. Consequently, the improvement observed after BoNT-A should be interpreted as an association within multimodal treatment rather than definitive evidence of an isolated BoNT-A effect.

The main limitation of this case is the inability to determine the independent effect of BoNT-A because diode laser therapy was continued during follow-up. In addition, pain was assessed using VAS alone, the follow-up period was limited to one month, and detailed procedural information such as dilution, injection volume, needle size, and injection depth was not documented in the source case. Therefore, the observed improvement should be interpreted as an association rather than proof of treatment efficacy.

CONCLUSION

Adjunctive subcutaneous botulinum toxin A was associated with a reduction in pain intensity from VAS 5 to VAS 3 within 3 days in a 60-year-old patient with thoracic postherpetic neuralgia, with the improvement maintained at 1 month. The finding supports the potential short-term analgesic role of local botulinum toxin A in PHN, while recognizing that concomitant therapies and the single-case design prevent attribution of the response to botulinum toxin A alone.

REFERENCES

Apalla, Z., Sotiriou, E., Lallas, A., Lazaridou, E., & Ioannides, D. (2013). Botulinum toxin A in postherpetic neuralgia: A parallel, randomized, double-blind, single-dose, placebo-controlled trial. The Clinical Journal of Pain, 29(10), 857–864. https://doi.org/10.1097/AJP.0b013e31827a72d4

Chen, L., Zhang, Y., Chen, Y., Wang, T., Sun, K., Tang, H., & others. (2022). Efficacy and safety of botulinum toxin A and pulsed radiofrequency on postherpetic neuralgia: A randomized clinical trial. Contrast Media & Molecular Imaging, 2022, 1579937. https://doi.org/10.1155/2022/1579937

Cruces Muñoz, P. A. (2024). Toxina botulínica en neuralgia posherpética del trigémino de diez años de evolución. Acta Neurológica Colombiana, 40(4). https://actaneurologica.com/index.php/anc/article/view/1797

Ding, X. D., Zhong, J., Liu, Y. P., & Chen, H. X. (2017). Botulinum toxin for treating post-herpetic neuralgia. Iranian Journal of Public Health, 46(5), 608–611. https://pmc.ncbi.nlm.nih.gov/articles/PMC5442272/

Gónima Valero, E., Mendoza, W. A. S., Sarmiento, D. A., & Amaya, S. (2023). Analgesic treatment approach for postherpetic neuralgia: A narrative review. Journal of Pain and Palliative Care Pharmacotherapy, 37(2), 184–193. https://doi.org/10.1080/15360288.2023.2174414

Jeon, Y. H. (2015). Herpes zoster and postherpetic neuralgia: Practical consideration for prevention and treatment. Korean Journal of Pain, 28(3), 177–184. https://doi.org/10.3344/kjp.2015.28.3.177

Johnson, R. W. (2002). Consequences and management of pain in herpes zoster. The Journal of Infectious Diseases, 186(Suppl. 1), S83–S90. https://doi.org/10.1086/368197

Li, X. L., Zeng, X., Zeng, S., He, H. P., Zeng, Z., Peng, L. L., & others. (2020). Botulinum toxin A treatment for post-herpetic neuralgia: A systematic review and meta-analysis. Experimental and Therapeutic Medicine, 19(2), 1058–1064. https://doi.org/10.3892/etm.2019.8354

Lim, D. Z. J., Tey, H. L., Salada, B. M. A., Oon, J. E. L., Seah, E. J. D., Chandran, N. S., & others. (2024). Herpes zoster and post-herpetic neuralgia—Diagnosis, treatment, and vaccination strategies. Pathogens, 13(7), 596. https://doi.org/10.3390/pathogens13070596

Liu, H. T., Tsai, S. K., Kao, M. C., & Hu, J. S. (2006). Botulinum toxin A relieved neuropathic pain in a case of post-herpetic neuralgia. Pain Medicine, 7(1), 89–91. https://doi.org/10.1111/j.1526-4637.2006.00026.x

Liu, Q., Han, J., & Zhang, X. (2024). Peripheral and central pathogenesis of postherpetic neuralgia. Skin Research and Technology, 30(8), e13867. https://doi.org/10.1111/srt.13867

Nalamachu, S., & Morley-Forster, P. (2012). Diagnosing and managing postherpetic neuralgia. Drugs & Aging, 29(11), 863–869. https://doi.org/10.1007/s40266-012-0011-7

Nadiva, S. K., Hidayati, A. N., Basuki, M., & Machin, A. (2024). Risk factors and complications in herpes zoster patients at Dr. Soetomo General Academic Hospital, Surabaya. JUXTA: Jurnal Ilmiah Mahasiswa Kedokteran Universitas Airlangga, 15(2), 106–112. https://e-journal.unair.ac.id/JUXTA/article/view/52127

Oliveira, K. M., Barreto, E. S. R., Alencar, V. B., Lins-Kusterer, L. E. F., Azi, L. M. T. de A., & Kraychete, D. C. (2024). The efficacy of botulinum toxin in neuropathic pain: A systematic review. Brazilian Journal of Pain, 18(5), 388–402. https://doi.org/10.5935/2595-0118.20240054

Peng, F., & Xia, T. B. (2023). Effects of intradermal botulinum toxin injections on herpes zoster related neuralgia. Infection and Drug Resistance, 16, 2159–2165. https://doi.org/10.2147/IDR.S405551

Ri, S., Kivi, A., & Wissel, J. (2021). The safety and effect of local botulinum toxin A injections for long-term management of chronic pain in post-herpetic neuralgia: Literature review and cases report treated with incobotulinumtoxin A. Journal of Personalized Medicine, 11(8), 758. https://doi.org/10.3390/jpm11080758

Rohmayanti, I. D., & Kurniawan, S. N. (2023). Post-herpetic neuralgia. Journal of Pain, Vertigo and Headache, 4(1), 1–6. https://jphv.ub.ac.id/index.php/jphv/article/view/249

Shackleton, T., Ram, S., Black, M., Ryder, J., Clark, G. T., & Enciso, R. (2016). The efficacy of botulinum toxin for the treatment of trigeminal and postherpetic neuralgia: A systematic review with meta-analyses. Oral Surgery, Oral Medicine, Oral Pathology and Oral Radiology, 122(1), 61–71. https://doi.org/10.1016/j.oooo.2016.04.002

Song, J., Choi, S. S., Choi, S. J., & Lee, C. H. (2024). Efficacy of botulinum type A injection for the treatment of postherpetic neuralgia and pruritus persisting for more than four years: A case report. Medicina, 60(8), 1317. https://doi.org/10.3390/medicina60081317

van Wijck, A. J. M., Wallace, M., Mekhail, N., & van Kleef, M. (2011). Herpes zoster and post-herpetic neuralgia. Pain Practice, 11(1), 88–97. https://doi.org/10.1111/j.1533-2500.2010.00428.x

Wang, H., & Lin, P. (2024). Efficacy and safety of subcutaneous injection of botulinum toxin in the treatment of Chinese postherpetic neuralgia compared to analgesics: A systematic review and meta-analysis. Frontiers in Neurology, 15, 1479931. https://doi.org/10.3389/fneur.2024.1479931

Wijaya, E., Winaya, K. K., & Utami, D. N. T. (2025). Efficacy of botulinum toxin type A (BTX-A) injection for the treatment of postherpetic neuralgia: A literature review. Jurnal Biomedika dan Kesehatan, 8(1), 87–97. https://jbiomedkes.org/index.php/jbk/article/view/642

Yang, F., Yu, S., Fan, B., Liu, Y., Chen, Y. X., Kudel, I., & others. (2019). The epidemiology of herpes zoster and postherpetic neuralgia in China: Results from a cross-sectional study. Pain and Therapy, 8(2), 249–259. https://doi.org/10.1007/s40122-019-0127-z